



## FEMORAL OSTEOTOMIES FOR OSTEONECROSIS OF THE FEMORAL HEAD

Goro Motomura , Yasuharu Nakashima 

Department of Orthopaedic Surgery, Graduate School of Medical Sciences, Kyushu University, Fukuoka, Japan

Author for correspondence: Goro Motomura: [goromoto@ortho.med.kyushu-u.ac.jp](mailto:goromoto@ortho.med.kyushu-u.ac.jp)

Submitted: 30 March 2021. Accepted: 5 August 2021. Published: 2 November 2021

### Abstract

Femoral osteotomy is performed for osteonecrosis of the femoral head to prevent the progression of collapse and promote the repair process by transposing the necrotic lesion to the nonweight-bearing portion. The purpose of this review article was to summarize the current knowledge on two types of femoral osteotomy: transtrochanteric anterior or posterior rotational osteotomy and transtrochanteric curved varus osteotomy, both of which are currently performed for osteonecrosis, mainly in Japan and Korea. Osteotomy can be expected to cure osteonecrosis, and no matter how much the durability of artificial joints improves, there will always be young patients for whom the procedure is indicated. We should continue to verify the results of this surgery and refine the techniques involved.

**Keywords:** *femoral osteotomy; joint-preserving surgery; femoral head collapse; osteonecrosis*

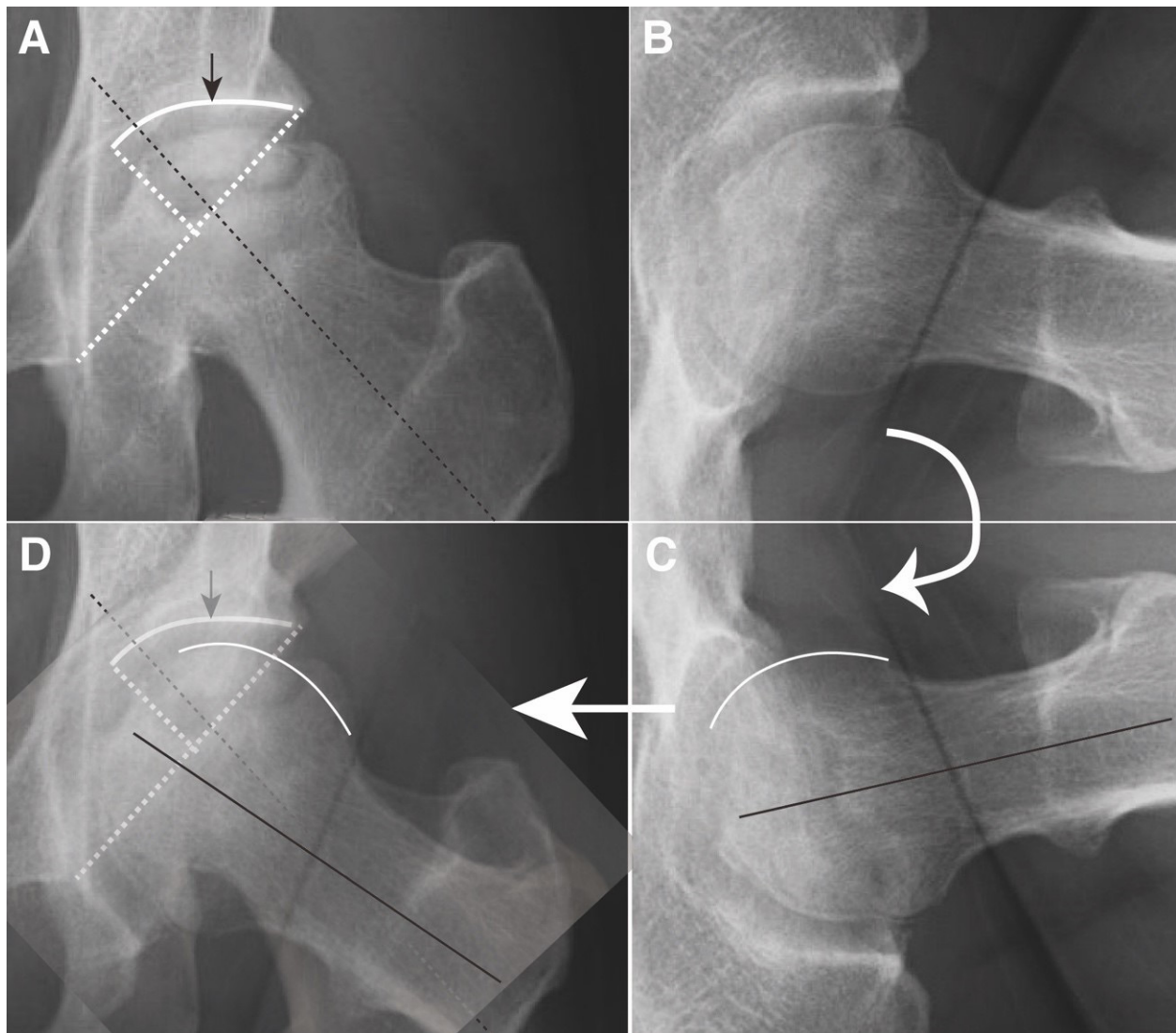
### CONCEPT OF FEMORAL OSTEOTOMY

In the natural course of osteonecrosis of the femoral head (ONFH), a subchondral fracture occurs depending on the size and location of the necrotic lesion, resulting in femoral head collapse.<sup>1</sup> The presence of a collapsed necrotic lesion in the weight-bearing area often results in further progression of collapse due to continuous loading, followed by secondary osteoarthritis that eventually necessitates replacement arthroplasty no matter how young the patient is. On the other hand, when the necrotic lesion is located in the nonweight-bearing part of the femoral head, it will not collapse.<sup>2</sup> Accordingly, the concept of femoral osteotomy is to prevent the progression of collapse and promote the repair process by transposing the necrotic lesion to the nonweight-bearing portion.

### INDICATION FOR FEMORAL OSTEOTOMY

A necessary condition for osteotomy is the presence of a sufficiently intact articular surface on the anterior, posterior, or lateral portion of the femoral head. This can be assessed based on the postoperative intact ratio, defined as the ratio of the transposed intact articular surface of the femoral head to the weight-bearing surface of the acetabulum (Figure 1).<sup>3,4</sup> In general, a minimum postoperative intact ratio of at least 34% is necessary to prevent progressive collapse.<sup>4</sup> The type of osteotomy is determined based on the location of the intact area.

Osteotomy is not generally indicated during the asymptomatic pre-collapse stages, such as ARCO stages I and II.<sup>5</sup> The procedure is ideally performed shortly after the onset of pain and when the occurrence of collapse is suggested by radiological findings such



**Figure 1.** A method for estimating the postoperative intact ratio using preoperative radiographs (an example involving transtrochanteric anterior rotational osteotomy). (A) On a preoperative anteroposterior radiograph, the load-bearing portion of the left acetabulum is shown by the white curved line. The black arrow indicates about 40% point of the load-bearing portion of the acetabulum. The black dotted line indicates the femoral neck axis. (B) A preoperative lateral view of the left femoral head. The posterior articular surface of the femoral head is intact. (C) A mirror image of the lateral view (Figure B). The black line indicates the femoral neck axis. The white curved line indicates the posterior intact articular surface of the femoral head. (D) Figure A is superimposed onto a rotated version of Figure C. The posterior intact articular surface of the femoral head occupies over 40% point of the load-bearing portion of the acetabulum with intended varus angulation of the femoral neck axis.

as signs of subchondral fracture on radiographs or bone marrow edema on magnetic resonance imaging (MRI).<sup>6,7</sup> At the latest, surgery should be performed before radiographs show joint space narrowing.

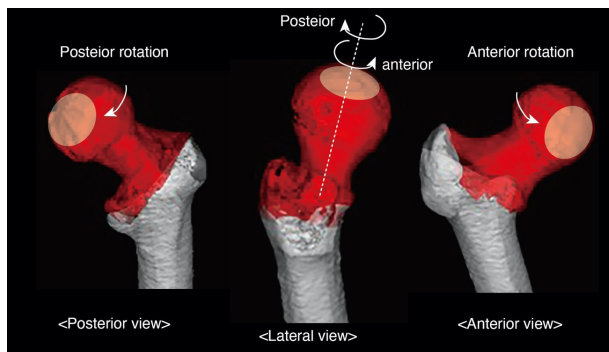
As the durability of artificial joints has improved, osteotomy is now indicated for patients below 50 years of age who meet the above conditions and who wish to undergo joint-preserving surgery. Currently,

femoral osteotomy is not widely performed outside Asian countries. One disadvantage of this procedure is the lengthy postoperative rehabilitation required; countries in which such rehabilitation is not feasible, either due to the medical system or to patient expectations, are unlikely to offer this surgery.

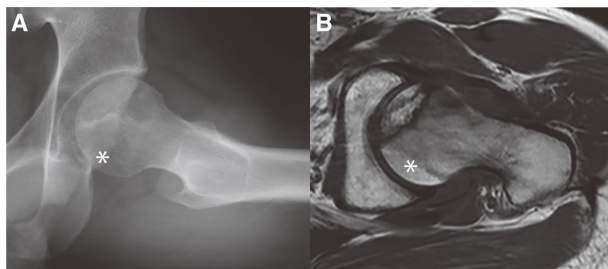
### TRANSTROCHANTERIC ROTATIONAL OSTEOTOMY

#### *Indication and preoperative planning*

Transtrochanteric anterior rotational osteotomy (ARO) (Figure 2)<sup>8</sup> is indicated when at least one-third of the posterior articular surface is intact on a lateral radiograph and oblique axial MRI scans (Figure 3). The postoperative intact ratio after ARO can be estimated preoperatively using a mirror



**Figure 2.** A three-dimensional model of transtrochanteric rotational osteotomy.

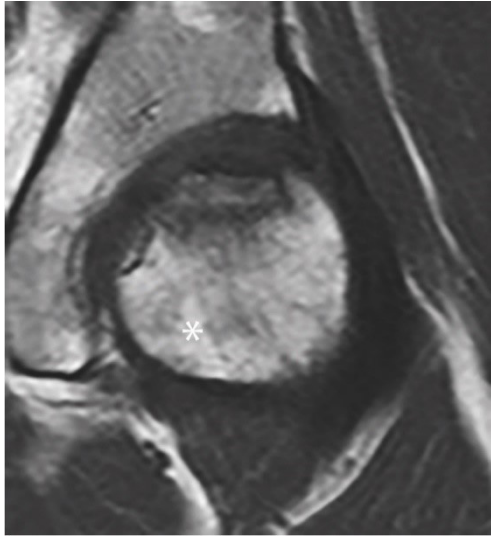


**Figure 3.** (A) A preoperative lateral view of the left femoral head. The posterior articular surface of the femoral head looks intact (asterisk). (B) An oblique axial view of magnetic resonance imaging. The posterior articular surface of the femoral head is confirmed to be intact (asterisk).

image of the lateral view (Figure 1). Based on the results of a recent study examining factors affecting joint space narrowing after ARO, a postoperative intact ratio of 40% or higher is targeted.<sup>9</sup> If the estimated postoperative intact ratio is less than 40%, the degree of intentional varus angulation necessary to achieve an intact ratio of 40% is examined.<sup>10</sup> The intertrochanteric osteotomy plane, defined by the two intertrochanteric osteotomy lines, is decided based on the degrees of intentional varus angulation and preoperative femoral anteversion.<sup>10,11</sup> In order to achieve a sufficient postoperative intact ratio and to maintain femoral anteversion, three-dimensional CT-based simulation is useful.<sup>11</sup> To enable preoperative planning even in the absence of simulation software, approximation equations for determining the two osteotomy lines have been developed based on simulation data.<sup>11</sup>

In contrast with ARO, posterior rotational osteotomy (PRO) (Figure 2)<sup>12</sup> is indicated when at least one-third of the anterior articular surface is intact on a lateral radiograph and oblique axial MRI scans. Unlike ARO, posterior rotation makes it possible for a proximal bone fragment that includes the femoral head to be moved without stretching the nutrient vessels, thus allowing rotation of more than 90 degrees.<sup>13</sup> Therefore, PRO is indicated, if the anteroinferior portion of the femoral head is intact (Figure 4). The postoperative intact ratio after PRO is estimated preoperatively using the lateral view. The target value for the postoperative intact ratio is 37% or higher based on the results of a previous study.<sup>14</sup> As with ARO, the two intertrochanteric osteotomy lines are determined by considering the degrees of intentional varus angulation and preoperative femoral anteversion.<sup>10,15</sup> Three-dimensional CT-based simulation is useful for preoperative planning, especially in complicated cases requiring more than 90 degrees rotation.<sup>15</sup> The approximation equations for determining the two osteotomy lines have also been developed based on simulation data.<sup>15</sup>

In PRO, the collapsed necrotic lesion is positioned within the acetabulum after surgery,<sup>12</sup> and therefore this procedure is considered to be more advantageous in terms of joint stability than ARO



**Figure 4.** A coronal magnetic resonance imaging view. High-degree transtrochanteric posterior rotational osteotomy is indicated if the anteroinferior portion of the femoral head (asterisk) is intact.

**Table 1.** Indications for Different Osteotomies and their Advantages and Disadvantages

	Indications (location of the intact area)	Advantages	Disadvantages
ARO	Posterior area		Invasive**
PRO	Anterior area	Joint stability*	
TCVO	Lateral area	Less invasive***	

ARO, anterior rotational osteotomy; PRO, transtrochanteric posterior rotational osteotomy; TCVO, transtrochanteric curved varus osteotomy. \*Advantages compared to ARO. \*\*Disadvantages compared to TCVO. \*\*\*Advantages compared to ARO or PRO.

(Table 1). Therefore, if there are indications for both surgeries, PRO is recommended.

**Operative and postoperative protocols**

According to the original method,<sup>10</sup> transtrochanteric rotational osteotomy is performed in the following order: (i) osteotomy of the greater trochanter, (ii) circumferential capsular exposure and capsulotomy, (iii) intertrochanteric osteotomy, (iv) 90-degree anterior rotation or 90- to 130-degree posterior

rotation of the proximal fragment, (v) fixation of the intertrochanteric osteotomy site, and (vi) reattachment of the greater trochanter. Before the intertrochanteric osteotomy, two Kirschner wires oriented perpendicularly to the femoral neck are inserted into the intertrochanteric region through the cut surface of the greater trochanter. The intertrochanteric osteotomy plane is determined radiographically based on preoperative planning. During this procedure, it is important to preserve the posterior column artery, which is a branch of the medial femoral circumflex artery that supplies nutrients to the femoral head. The posterior column artery is located in the adipose tissue underneath the quadratus femoris muscle. It is important to never expose or release the posterior column artery. When the obturator externus is exposed and released to rotate the proximal fragment, careful and minimal release of the quadratus femoris muscle is recommended. In addition, during anterior rotation of the proximal fragment, attention must be paid to the location of the posterior column artery to avoid excessive tension on the artery.

The postoperative protocol is performed as follows: Use of a wheelchair begins around 2 days after surgery, and passive range-of-motion exercises begin 5 days after surgery. Nonweight-bearing is continued until 5 weeks after surgery, at which time patients are allowed to start walking exercises with partial weight-bearing. Full weight-bearing is permitted approximately 4 to 6 months after surgery.

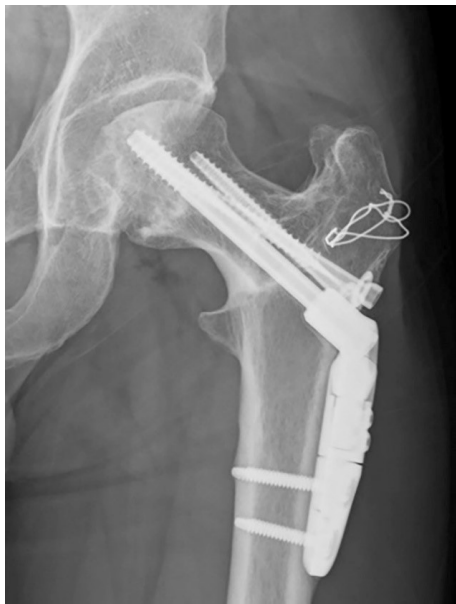**Surgical outcomes**

Since 1978, when this technique was first introduced, many case series studies have been reported. In the past, there were several reports from Europe and the United States,<sup>16–18</sup> but recently there have only been reports from Asia, mainly from Japan and Korea.<sup>19–22</sup> The 10-year joint preservation rates have been reported to be around 60–80% (Table 2).<sup>19–22</sup> Since one study reported that the 5-year preservation rate of 41 conservatively managed collapsed hip joints was about 50%,<sup>19</sup> it is likely that transtrochanteric rotational osteotomy effectively preserves hip joints (Figure 5).

Regarding patient satisfaction levels, several studies have assessed patient-reported outcomes.<sup>19,23</sup> In a

**Table 2.** Results of Transtrochanteric Rotational Osteotomy

Authors (published year)	Number (hips)	Follow-up duration	Survival rate Endpoint: Conversion to THA
Kawano et al. (2020)	95	Minimum 10 years	85.4% at 10 years
Morita et al. (2017)	111	18.2 (3–26) years	59% at 15 years
Ha et al. (2010)	113	51.3 (36–108) Months	63.4% at 110 months
Biswal et al. (2009)	60	84 (18–156) Months	82% at 132 months
Rijnen et al. (2005)	26	8.7 (6.6–10) years	56% at 7 years



**Figure 5.** An anteroposterior radiograph of the left hip joint 9 years after transtrochanteric anterior rotational osteotomy. A sufficient portion of the weight-bearing area is intact, with no joint space narrowing.

prospective case series study with a short-term follow-up ranging from 1 to 6 years, significant improvements in hip joint function after ARO were shown by the self-reported Oxford Hip Score and the Physical Component Summary Score of Short Form-36.<sup>23</sup> In a case series study with a minimum follow-up of 10 years, the presence of osteoarthritic changes after ARO was found to be significantly associated with poor scores on both the Oxford Hip Score and the Short Form-12 Health Survey Physical Component Summary,<sup>19</sup> indicating that the presence of osteoarthritic changes can lead to lower satisfaction even among patients with long-term hip survival after ARO.

### *Tips for long-term success*

An appropriate indication, accurate surgical techniques, and strict postoperative management are all essential for successful outcomes.

In 1992, Sugioka reported that the outcomes of ARO were chiefly dependent on the transposed intact area, which should occupy more than 36% of the acetabular weight-bearing area as a result of adequate rotation and intentional varus position.<sup>3</sup> In 2000, Miyanishi et al. demonstrated that a minimum postoperative intact ratio of 34% was required after transtrochanteric rotational osteotomy to prevent progressive collapse of the transposed intact area of the femoral head over a 10-year period.<sup>4</sup> Thus, a postoperative intact ratio of more than 34% is indispensable for surgical success.

Some patients treated by transtrochanteric rotational osteotomy show gradual progression of joint space narrowing without progressive collapse of the transposed intact area, even though the postoperative intact ratio is over 34%. Subsequent studies have suggested that several factors are associated with joint space narrowing after transtrochanteric rotational osteotomy. Zhao et al. reported that a sufficient postoperative intact ratio was one of the main influences on the progression of joint space narrowing after ARO (cutoff point, 39.2%)<sup>8</sup> and PRO (cutoff point, 36.8%),<sup>14</sup> indicating that to prevent joint space narrowing, the postoperative intact ratio must be higher than that needed to prevent progressive collapse of the transposed intact area of the femoral head. Furthermore, Hisatome et al. demonstrated a significant correlation between progressive collapse of anteriorly transposed necrotic lesions and joint space narrowing after ARO.<sup>24</sup> Kubo et al. reported that the preoperative level of collapse (cutoff point,

2.98 mm) was independently associated with progressive collapse of the transposed necrotic lesion after ARO.<sup>25</sup> Accordingly, surgeons should pay attention not only to the postoperative intact ratio but also to the preoperative level of collapse. Based on these results, an attempt has been made to prevent progressive collapse with re-sphericalization during transtrochanteric rotational osteotomy using calcium phosphate cement filling.<sup>26</sup>

### TRANSTROCHANTERIC CURVED VARUS OSTEOTOMY

#### *Indication and preoperative planning*

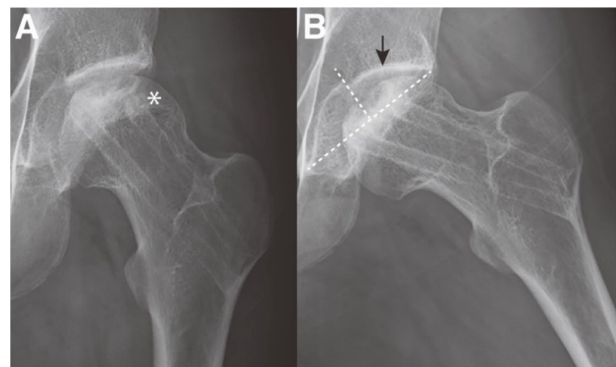
Transtrochanteric curved varus osteotomy (CVO) (Figure 6)<sup>27</sup> is indicated when the lateral articular surface is intact on an anteroposterior radiograph (Figure 7A). Preoperatively, the postoperative intact ratio after CVO can be estimated using a preoperative anteroposterior hip radiograph in maximum abduction (Figure 7B). A previous study demonstrated that the cutoff points of the postoperative intact ratio to prevent the progression of collapse and to prevent both the progression of collapse and joint-space narrowing were 33.6% and 41.9%, respectively.<sup>28</sup> Passive abduction of the hip of  $<20^\circ$  is considered a contraindication for this procedure due to the risk of postoperative adduction contracture.

Based on the fact that CVO is relatively less invasive than transtrochanteric rotational osteotomy,

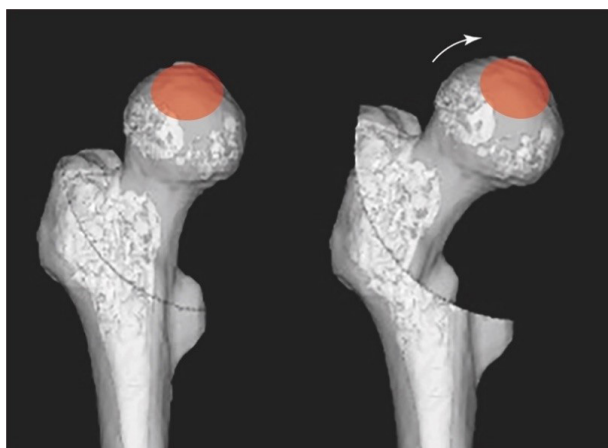
CVO is preferentially selected in patients who meet the criteria for both CVO and transtrochanteric rotational osteotomy.

#### *Operative and postoperative protocol*


According to the original method,<sup>27,28</sup> CVO is performed in the following order: (i) exposure of the lesser trochanter and lateral area of the intertrochanteric crest, (ii) attachment of the crescentic guide (Figure 8),<sup>28</sup> (iii) intertrochanteric osteotomy, (iv) achievement of the planned degree (about 20–30 degrees) of varus displacement of the proximal



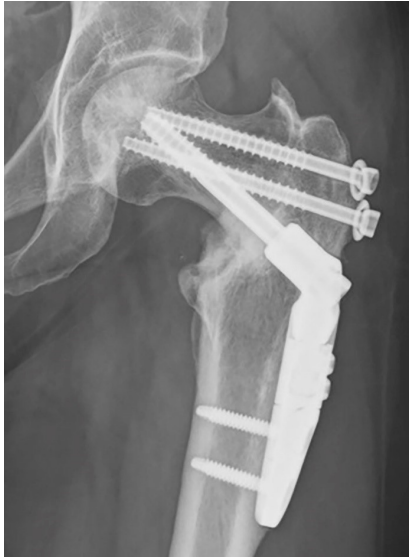**Figure 7.** (A) A preoperative anteroposterior radiograph. The lateral articular surface of the left femoral head is intact (asterisk). (B) A preoperative anteroposterior hip radiograph in maximum abduction estimates a postoperative intact ratio of more than 50% (black arrow).



**Figure 6.** A three-dimensional model of transtrochanteric curved varus osteotomy.



**Figure 8.** A crescentic guide for transtrochanteric curved varus osteotomy.



**Figure 9.** An anteroposterior radiograph of the left hip joint 6 years after transtrochanteric curved varus osteotomy. A sufficient portion of the weight-bearing area is intact, with no joint space narrowing.

fragment, and (v) fixation of the intertrochanteric osteotomy site. The crescentic guide is attached lateral to the intertrochanteric crest under fluoroscopic control to preserve the nutrient artery that arises from the medial femoral circumflex artery. An intertrochanteric curved osteotomy is made in the sagittal plane, perpendicular to the coronal plane (Figure 9).

The postoperative protocol is the same as that mentioned above in the section on transtrochanteric rotational osteotomy.

**Surgical outcomes**

Several case series studies have been reported from Japan and Korea, with 10-year joint preservation rates of around 80–90% (Table 3; Figure 8).<sup>28–31</sup> A recent case series study demonstrated that patient-reported functional outcomes and sporting activities

in patients <50 years old who underwent CVO or total hip arthroplasty were comparable after a mean follow-up period of 10 years.<sup>29</sup>

Although CVO is designed to minimize leg shortening, postoperative leg length discrepancy can still occur. Ikemura et al. demonstrated that the mean postoperative leg length discrepancy after CVO was 13 (4 to 25) mm, and the size of the discrepancy showed a strong correlation with varus angulation.<sup>32</sup> A recent report indicated that to avoid leg shortening after CVO, the central position of the osteotomy arc should not be lateral to the center of the femoral head.<sup>33</sup>

**Tips for long-term success**

Although the indications for CVO and the evaluation of its outcomes have been determined only by anteroposterior hip radiograph, a recent study showed that anterior localization of the necrotic lesion was associated with a risk of progressive collapse of the anterior necrotic lesion after CVO, resulting in subsequent osteoarthritic changes.<sup>34</sup> This means that the outcomes of CVO could be improved by preoperatively evaluating not only the extent of the lateral intact area but also the extent of the anterior necrotic lesion. Transtrochanteric ARO may be a reasonable procedure in these cases if the posterior intact area of the femoral head is sufficient.

**DISCUSSION**

Surgical strategy of joint-preserving surgery for ONFH depends on the stage of the disease. In the pre-collapse stage (asymptomatic stage), the purpose of the treatment is to prevent the occurrence of collapse. On the other hand, in the early stages after collapse, the goal of the treatment is to prevent further collapse progression and thereby achieve pain relief. We believe that the femoral osteotomy techniques

**Table 3.** Results of Transtrochanteric Curved Varus Osteotomy

Authors (published year)	Number (hips)	Follow-up duration	Survival rate Endpoint: Conversion to THA
Osawa et al. (2020)	65	11.5 (5–18) Years	91.8% at 10 years
Lee et al. (2017)	65	7.7 (5–11) years	89.2% at 9 years
Hamanishi et al. (2014)	53	75 (12–196) Months	52/53 hips
Zhao et al. (2010)	73	12.4 (5–31.1) years	67/73 hips

presented in this review article are established surgeries that should be considered as treatment options in the early stages after collapse, depending on the size and location of the necrotic lesion.

The indications for surgery comprise the most important factor contributing to successful osteotomy. The postoperative intact ratio, defined as the ratio of the transposed intact articular surface of the femoral head to the weight-bearing surface of the acetabulum, has been proven to be a reliable indicator for the prognosis of femoral osteotomies.<sup>9,14,28</sup> By examining the ratio preoperatively using X-rays and MRI, it is possible to determine if osteotomy is indicated.

Although strict postoperative management is considered to be essential for successful outcomes in femoral osteotomy, the long hospital stay that is necessary is an important issue. Even if osteotomy is indicated, some patients may choose total hip arthroplasty due to its shorter hospitalization period. It is necessary to pursue the possibility of shortening the time before loading.

#### SUMMARY

Osteotomy can be expected to cure osteonecrosis,<sup>35</sup> and no matter how much the durability of artificial joints improves, there will always be young patients for whom it is indicated. We need to continue to verify the results of the surgery and refine the techniques involved.

#### AUTHORS' CONTRIBUTIONS

Both authors were involved in the writing of the manuscript, and they also accorded their final approval of the manuscript.

#### REFERENCES

1. Ohzono K, Saito M, Sugano N, et al. The fate of nontraumatic avascular necrosis of the femoral head. A radiologic classification to formulate prognosis. *Clin Orthop Relat Res.* 1992;(277):73–8. <https://doi.org/10.1097/00003086-199204000-00009>
2. Mont MA, Zywił MG, Marker DR, et al. The natural history of untreated asymptomatic osteonecrosis of the femoral head: A systematic literature review. *J Bone Joint Surg Am.* 2010;92(12):2165–70. <https://doi.org/10.2106/JBJS.I.00575>
3. Sugioka Y, Hotokebuchi T, Tsutsui H. Transtrochanteric anterior rotational osteotomy for idiopathic and steroid-induced necrosis of the femoral head. Indications and long-term results. *Clin Orthop Relat Res.* 1992;277:111–20. <https://doi.org/10.1097/00003086-199204000-00013>
4. Miyanishi K, Noguchi Y, Yamamoto T, et al. Prediction of the outcome of transtrochanteric rotational osteotomy for osteonecrosis of the femoral head. *J Bone Joint Surg Br.* 2000;82(4):512–16. <https://doi.org/10.1302/0301-620X.82B4.0820512>
5. Yoon BH, Mont MA, Koo KH, et al. The 2019 revised version of association research circulation osseous staging system of osteonecrosis of the femoral head. *J Arthroplasty.* 2020;35(4):933–40. <https://doi.org/10.1016/j.arth.2019.11.029>
6. Hatanaka H, Motomura G, Ikemura S, et al. Differences in magnetic resonance findings between symptomatic and asymptomatic pre-collapse osteonecrosis of the femoral head. *Eur J Radiol.* 2019;112:1–6. <https://doi.org/10.1016/j.ejrad.2019.01.002>
7. Meier R, Kraus TM, Schaeffeler C, et al. Bone marrow oedema on MR imaging indicates ARCO stage 3 disease in patients with AVN of the femoral head. *Eur Radiol.* 2014;24(9):2271–8. <https://doi.org/10.1007/s00330-014-3216-8>
8. Sugioka Y. Transtrochanteric anterior rotational osteotomy of the femoral head in the treatment of osteonecrosis affecting the hip: A new osteotomy operation. *Clin Orthop Relat Res.* 1978;130:191–201. <https://doi.org/10.1097/00003086-197801000-00019>
9. Zhao G, Yamamoto T, Ikemura S, et al. Clinicoradiological factors affecting the joint space narrowing after transtrochanteric anterior rotational osteotomy for osteonecrosis of the femoral head. *J Orthop Sci.* 2012;17(4):390–6. <https://doi.org/10.1007/s00776-012-0238-4>
10. Sugioka Y. Transtrochanteric rotational osteotomy of the femoral head. In Macnicol MF, editor. *Color atlas and text of osteotomy of the hip.* London: Mosby-Wolfe; 1996. p. 145–55.
11. Sonoda K, Motomura G, Ikemura S, et al. Effects of intertrochanteric osteotomy plane and preoperative femoral anteversion on the postoperative morphology of the proximal femur in transtrochanteric anterior rotational osteotomy: 3D CT-based simulation study. *Orthop Traumatol Surg Res.* 2017;103(7):1005–10. <https://doi.org/10.1016/j.otsr.2017.06.012>
12. Sugioka Y, Yamamoto T. Transtrochanteric posterior rotational osteotomy for osteonecrosis. *Clin*



- Orthop Relat Res. 2008;466(5):1104–9. <https://doi.org/10.1007/s11999-008-0192-9>
13. Atsumi T, Kuroki Y. Modified Sugioka's osteotomy: more than 130 degrees posterior rotation for osteonecrosis of the femoral head with large lesion. *Clin Orthop Relat Res.* 1997;(334):98–107. <https://doi.org/10.1097/00003086-199701000-00013>
  14. Zhao G, Yamamoto T, Motomura G, et al. Radiological outcome analyses of transtrochanteric posterior rotational osteotomy for osteonecrosis of the femoral head at a mean follow-up of 11 years. *J Orthop Sci.* 2013;18(2):277–83. <https://doi.org/10.1007/s00776-012-0347-0>
  15. Xu M, Motomura G, Ikemura S, et al. Proximal femoral morphology after transtrochanteric posterior rotational osteotomy for osteonecrosis of the femoral head: A three-dimensional simulation study. *Orthop Traumatol Surg Res.* 2020;106(8):1569–74. <https://doi.org/10.1016/j.otsr.2020.07.003>
  16. Rijnen WH, Gardeniers JW, Westrek BL, et al. Sugioka's osteotomy for femoral-head necrosis in young Caucasians. *Int Orthop.* 2005;29(3):140–4. <https://doi.org/10.1007/s00264-005-0639-5>
  17. Langlais F, Fourastier J. Rotation osteotomies for osteonecrosis of the femoral head. *Clin Orthop Relat Res.* 1997;(343):110–23. <https://doi.org/10.1097/00003086-199710000-00021>
  18. Dean MT, Cabanela ME. Transtrochanteric anterior rotational osteotomy for avascular necrosis of the femoral head. Long-term results. *J Bone Joint Surg Br.* 1993;75(4):597–601. <https://doi.org/10.1302/0301-620X.75B4.8331115>
  19. Kawano K, Motomura G, Ikemura S, et al. Long-term hip survival and factors influencing patient-reported outcomes after transtrochanteric anterior rotational osteotomy for osteonecrosis of the femoral head: A minimum 10-year follow-up case series. *Mod Rheumatol.* 2020;30(1):184–90. <https://doi.org/10.1080/14397595.2018.1558917>
  20. Morita D, Hasegawa Y, Okura T, et al. Long-term outcomes of transtrochanteric rotational osteotomy for non-traumatic osteonecrosis of the femoral head. *Bone Joint J.* 2017;99-B(2):175–83. <https://doi.org/10.1302/0301-620X.99B2.BJJ-2016-0417.R2>
  21. Ha YC, Kim HJ, Kim SY, et al. Effects of age and body mass index on the results of transtrochanteric rotational osteotomy for femoral head osteonecrosis. *J Bone Joint Surg Am.* 2010;92(2):314–21. <https://doi.org/10.2106/JBJS.H.01020>
  22. Biswal S, Hazra S, Yun HH, et al. Transtrochanteric rotational osteotomy for nontraumatic osteonecrosis of the femoral head in young adults. *Clin Orthop Relat Res.* 2009;467(6):1529–37. <https://doi.org/10.1007/s11999-008-0696-3>
  23. Kubo Y, Yamamoto T, Motomura G, et al. Patient-reported outcomes of femoral osteotomy and total hip arthroplasty for osteonecrosis of the femoral head: A prospective case series study. *Springerplus.* 2016;5(1):1880. <https://doi.org/10.1186/s40064-016-3576-4>
  24. Hisatome T, Yasunaga Y, Takahashi K, et al. Progressive collapse of transposed necrotic area after transtrochanteric rotational osteotomy for osteonecrosis of the femoral head induces osteoarthritic change. Mid-term results of transtrochanteric rotational osteotomy for osteonecrosis of the femoral head. *Arch Orthop Trauma Surg.* 2004;124(2):77–81. <https://doi.org/10.1007/s00402-003-0610-0>
  25. Kubo Y, Motomura G, Ikemura S, et al. Factors influencing progressive collapse of the transposed necrotic lesion after transtrochanteric anterior rotational osteotomy for osteonecrosis of the femoral head. *Orthop Traumatol Surg Res.* 2017;103(2):217–22. <https://doi.org/10.1016/j.otsr.2016.10.019>
  26. Motomura G, Yamamoto T, Kubo Y, et al. Transtrochanteric anterior rotational osteotomy combined with ee-sphericalization of the collapsed femoral head using calcium phosphate cement filling. *Surg Technol Int.* 2020;36:347–50.
  27. Nishio A, Sugioka Y. A new technique of the varus osteotomy at the upper end of the femur. *Orthop Trauma.* 1971;20:381–386 [in Japanese]. <https://doi.org/10.5035/nishiseisai.20.381>
  28. Zhao G, Yamamoto T, Ikemura S, et al. Radiological outcome analysis of transtrochanteric curved varus osteotomy for osteonecrosis of the femoral head at a mean follow-up of 12.4 years. *J Bone Joint Surg Br.* 2010;92(6):781–6. <https://doi.org/10.1302/0301-620X.92B6.23621>
  29. Osawa Y, Seki T, Okura T, et al. Curved intertrochanteric varus osteotomy vs total hip arthroplasty for osteonecrosis of the femoral head in patients under 50 years old. *J Arthroplasty.* 2020;35(6):1600–5. <https://doi.org/10.1016/j.arth.2020.01.026>
  30. Lee YK, Park CH, Ha YC, et al. Comparison of surgical parameters and results between curved varus osteotomy and rotational osteotomy for osteonecrosis of the femoral head. *Clin Orthop Surg.* 2017;9(2):160–8. <https://doi.org/10.4055/cios.2017.9.2.160>
  31. Hamanishi M, Yasunaga Y, Yamasaki T, et al. The clinical and radiographic results of intertrochanteric curved varus osteotomy for idiopathic osteonecrosis of the femoral head. *Arch Orthop Trauma*

- Surg. 2014;134(3):305–10. <https://doi.org/10.1007/s00402-013-1919-y>
32. Ikemura S, Yamamoto T, Jingushi S, et al. Leg-length discrepancy after transtrochanteric curved varus osteotomy for osteonecrosis of the femoral head. *J Bone Joint Surg Br.* 2007;89(6):725–9. <https://doi.org/10.1302/0301-620X.89B6.18499>
33. Asano T, Takahashi D, Shimizu T, et al. A mathematical model for predicting postoperative leg shortening after curved intertrochanteric varus osteotomy for osteonecrosis of the femoral head. *PLoS One.* 2018;13(12):e0208818. <https://doi.org/10.1371/journal.pone.0208818>
34. Kubo Y, Motomura G, Ikemura S, et al. Effects of anterior boundary of the necrotic lesion on the progressive collapse after varus osteotomy for osteonecrosis of the femoral head. *J Orthop Sci.* 2020;25(1):145–51. <https://doi.org/10.1016/j.jos.2019.02.014>
35. Yamamoto T, Ikemura S, Iwamoto Y, et al. The repair process of osteonecrosis after a transtrochanteric rotational osteotomy. *Clin Orthop Relat Res.* 2010;468(12):3186–91. <https://doi.org/10.1007/s11999-010-1384-7>